A 5-month-old boy with chronic diarrhea and failure to thrive is found to have a low blood T-lymphocyte count and severely decreased serum immunoglobulin. After thorough evaluation, an experimental treatment is proposed to his parents. The therapy consists of infecting the patient's cells with a retroviral vector containing the gene for a protein that is deficient in this patient. Which of the following proteins is most likely coded by this gene?

- A. Adenosine deaminase
- B. Myeloperoxidase
- C. NADPH oxidase
- D. Reverse transcriptase
- E. Xanthine oxidase

Submit

A 5-month-old boy with chronic diarrhea and failure to thrive is found to have a low blood T-lymphocyte count and severely decreased serum immunoglobulin. After thorough evaluation, an experimental treatment is proposed to his parents. The therapy consists of infecting the patient's cells with a retroviral vector containing the gene for a protein that is deficient in this patient. Which of the following proteins is most likely coded by this gene?

- ✓ A. Adenosine deaminase (84%)
- B. Myeloperoxidase (4%)
- C. NADPH oxidase (5%)
- D. Reverse transcriptase (4%)
- E. Xanthine oxidase (1%)

Omitted
Correct answer
A

84%
Answered correctly

05 secs
Time Spent

05/18/2020
Last Updated

Explanation

This patient has manifestations characteristic of **severe combined immunodeficiency** (SCID). **Adenosine deaminase (ADA) deficiency** is the second most common cause of SCID, after X-linked SCID (eg, IL-2 receptor mutation). ADA is present throughout the human body and functions to eliminate excess adenosine from cells by deaminating adenosine to inosine. Adenosine accumulation is highly toxic to mitotically active cells such as developing lymphocytes; ADA insufficiency leads to widespread death of both T- and B-lymphocytes with resultant combined **cellular and humoral immunodeficiency**. Because both humoral and cell-mediated immunity are deficient in these patients, they are vulnerable to recurrent, severe infections by bacteria, viruses, and fungi.

This patient has manifestations characteristic of **severe combined immunodeficiency** (SCID). **Adenosine deaminase (ADA) deficiency** is the second most common cause of SCID, after X-linked SCID (eg, IL-2 receptor mutation). ADA is present throughout the human body and functions to eliminate excess adenosine from cells by deaminating adenosine to inosine. Adenosine accumulation is highly toxic to mitotically active cells such as developing lymphocytes; ADA insufficiency leads to widespread death of both T- and B-lymphocytes with resultant combined **cellular and humoral immunodeficiency**. Because both humoral and cell-mediated immunity are deficient in these patients, they are vulnerable to recurrent, severe infections by bacteria, viruses, and fungi.

Treatment is with hematopoietic (bone marrow) transplantation, but **retroviral gene therapy** is a promising treatment for patients without an HLA match. Retroviral vectors are used to infect patient hematopoietic stem cells with the genetic code for ADA, resulting in production of ADA by all daughter cells of that stem cell.

(Choice B) Myeloperoxidase is a neutrophil enzyme that helps kill phagocytosed organisms by catalyzing the production of hypochlorite (bleach) from hydrogen peroxide and chloride. A deficiency of this enzyme results in immunodeficiency characterized by recurrent *Candida* infections.

(Choice C) NADPH oxidase is the enzyme that is deficient in chronic granulomatous disease (CGD). Without NADPH oxidase, neutrophils are unable to form reactive oxygen species such as superoxide. CGD manifests clinically with recurrent infections by catalase-producing organisms (eg, staphylococci). Dihydrorhodamine or nitroblue tetrazolium testing can be used to diagnose CGD.

(Choice D) Reverse transcriptase is a retroviral enzyme that converts viral genomic RNA (in this case, ADA) to DNA. Although it plays a role in the effectiveness of the retrovirus as a vector for the treatment of SCID, reverse transcriptase is not deficient in patients with this condition.

(Choice E) Xanthine oxidase is the enzyme responsible for the formation of uric acid from hypoxanthine and xanthine and is essential as the final step of purine degradation. Xanthine oxidase deficiency leads to abnormally low levels of uric acid in the serum; it can also lead to renal calculi due to the relative insolubility of xanthine at urine's pH level.

Educational objective:
The second most common cause of severe combined immunodeficiency is autosomal recessive deficiency of adenosine deaminase, an enzyme necessary for the elimination of excess adenosine within cells. Toxic levels of adenosine accumulate within lymphocytes in this condition, leading to lymphocyte cell death and resultant cellular and humoral immunodeficiency. Patients with this condition can be treated with hematopoietic cell transplantation or gene therapy.

humoral immunodeficiency. Because both humoral and cell-mediated immunity are deficient in these patients, they are vulnerable to recurrent, severe infections by bacteria, viruses, and fungi.

Treatment is with hematopoietic (bone marrow) transplantation, but **retroviral gene therapy** is a promising treatment for patients without an HLA match. Retroviral vectors are used to infect patient hematopoietic stem cells with the genetic code for ADA, resulting in production of ADA by all daughter cells of that stem cell.

(Choice B) Myeloperoxidase is a neutrophil enzyme that helps kill phagocytosed organisms by catalyzing the production of hypochlorite (bleach) from hydrogen peroxide and chloride. A deficiency of this enzyme results in immunodeficiency characterized by recurrent *Candida* infections.

(Choice C) NADPH oxidase is the enzyme that is deficient in chronic granulomatous disease (CGD). Without NADPH oxidase, neutrophils are unable to form reactive oxygen species such as superoxide. CGD manifests clinically with recurrent infections by catalase-producing organisms (eg, staphylococci). Dihydrorhodamine or nitroblue tetrazolium testing can be used to diagnose CGD.

(Choice D) Reverse transcriptase is a retroviral enzyme that converts viral genomic RNA (in this case, ADA) to DNA. Although it plays a role in the effectiveness of the retrovirus as a vector for the treatment of SCID, reverse transcriptase is not deficient in patients with this condition.

(Choice E) Xanthine oxidase is the enzyme responsible for the formation of uric acid from hypoxanthine and xanthine and is essential as the final step of purine degradation. Xanthine oxidase deficiency leads to abnormally low levels of uric acid in the serum; it can also lead to renal calculi due to the relative insolubility of xanthine at urine's pH level.

Educational objective:
The second most common cause of severe combined immunodeficiency is autosomal recessive deficiency of adenosine deaminase, an enzyme necessary for the elimination of excess adenosine within cells. Toxic levels of adenosine accumulate within lymphocytes in this condition, leading to lymphocyte cell death and resultant cellular and humoral immunodeficiency. Patients with this condition can be treated with hematopoietic cell transplantation or gene therapy.

Pathophysiology	Allergy & Immunology	Severe combined immunodeficiency disease
Subject	System	Topic

Copyright © UWorld. All rights reserved.

A 4-year-old boy has just recovered from severe staphylococcal pneumonia. He has a history of recurrent lymphadenitis and skin infections. Dihydrorhodamine flow cytometry testing reveals an absence of the green fluorescence produced by normal neutrophils. This patient's condition is most likely due to impaired activity of which of the following enzymes?

A. Adenosine deaminase

B. Cytochrome c oxidase

C. Myeloperoxidase

D. NADPH oxidase

E. Pyruvate kinase

Submit

A 4-year-old boy has just recovered from severe staphylococcal pneumonia. He has a history of recurrent lymphadenitis and skin infections. Dihydrorhodamine flow cytometry testing reveals an absence of the green fluorescence produced by normal neutrophils. This patient's condition is most likely due to impaired activity of which of the following enzymes?

A. Adenosine deaminase (4%)
B. Cytochrome c oxidase (1%)
C. Myeloperoxidase (24%)
✓ D. NADPH oxidase (69%)
E. Pyruvate kinase (0%)

Omitted
Correct answer
D

69%
Answered correctly

01 sec
Time Spent

05/12/2020
Last Updated

Explanation

Features of chronic granulomatous disease	
Pathogenesis	• Inactivating mutation affecting **NADPH oxidase** • Impaired respiratory burst inhibits phagocytic **intracellular killing**
Clinical manifestations	• Recurrent infections with **catalase-positive** bacteria & fungi • Lungs, skin, lymph nodes & liver most commonly involved • Diffuse **granuloma formation**

Features of chronic granulomatous disease	
Pathogenesis	• Inactivating mutation affecting **NADPH oxidase** • Impaired respiratory burst inhibits phagocytic **intracellular killing**
Clinical manifestations	• Recurrent infections with **catalase-positive** bacteria & fungi • Lungs, skin, lymph nodes & liver most commonly involved • Diffuse **granuloma formation**
Diagnosis	Measurement of **neutrophil superoxide production**: • DHR flow cytometry (preferred) • NBT testing

DHR = dihydrorhodamine; NBT = nitroblue tetrazolium.

This patient's abnormal flow cytometry findings are characteristic of **chronic granulomatous disease (CGD)**, an X-linked condition caused by **NADPH oxidase deficiency**. NADPH oxidase is a membrane-bound complex that catalyzes the reduction of O_2 to O_2^- (superoxide) within phagolysosomes (ie, oxidative burst), facilitating intracellular killing of organisms ingested by phagocytes. Patients with CGD have **recurrent bacterial and fungal infections** (eg, pneumonia, skin and organ abscesses, suppurative adenitis, osteomyelitis).

Diagnostic tests for CGD involve the assessment of neutrophil superoxide production:

- **Nitroblue tetrazolium (NBT)** testing involves adding NBT to a sample of the patient's neutrophils. Properly functioning neutrophils produce reactive oxygen species that reduce the yellow or colorless NBT to **dark blue** formazan that precipitates within the cells.
- **Dihydrorhodamine (DHR)** testing assesses the production of superoxide radicals by measuring the conversion of DHR to rhodamine, a **fluorescent green** compound that can be detected on flow cytometry.

Patients with deficient NADPH oxidase activity have abnormal NBT testing (ie, no change in color) and an absence of fluorescence on DHR flow cytometry.

(Choice A) Adenosine deaminase deficiency is an autosomal recessive disorder that is the second most common cause of severe combined

NADPH oxidase deficiency. NADPH oxidase is a membrane-bound complex that catalyzes the reduction of O_2 to O_2^- (superoxide) within phagolysosomes (ie, oxidative burst), facilitating intracellular killing of organisms ingested by phagocytes. Patients with CGD have **recurrent bacterial and fungal infections** (eg, pneumonia, skin and organ abscesses, suppurative adenitis, osteomyelitis).

Diagnostic tests for CGD involve the assessment of neutrophil superoxide production:

- **Nitroblue tetrazolium (NBT)** testing involves adding NBT to a sample of the patient's neutrophils. Properly functioning neutrophils produce reactive oxygen species that reduce the yellow or colorless NBT to **dark blue** formazan that precipitates within the cells.
- **Dihydrorhodamine (DHR)** testing assesses the production of superoxide radicals by measuring the conversion of DHR to rhodamine, a **fluorescent green** compound that can be detected on flow cytometry.

Patients with deficient NADPH oxidase activity have abnormal NBT testing (ie, no change in color) and an absence of fluorescence on DHR flow cytometry.

(Choice A) Adenosine deaminase deficiency is an autosomal recessive disorder that is the second most common cause of severe combined immunodeficiency. This condition results in a profound decrease in B and T lymphocytes with variable immunoglobulin deficiencies.

(Choice B) Cytochrome c oxidase is a multi-subunit complex that acts as the terminal enzyme of the mitochondrial respiratory chain. Deficiency is most commonly due to autosomal recessive mutations and results in variable myopathic and encephalopathic findings.

(Choice C) Myeloperoxidase is an enzyme found in neutrophil azurophilic granules that aids in intracellular killing by catalyzing the production of hypochlorite (bleach) from hydrogen peroxide and chloride. Myeloperoxidase deficiency results in recurrent *Candida* infections. DHR fluorescence can be slightly reduced with impaired activity of this enzyme, but absence of fluorescence on DHR testing in a child with severe staphylococcal infections is more characteristic of CGD.

(Choice E) Pyruvate kinase deficiency is a common cause of chronic hemolytic anemia.

Educational objective:
Chronic granulomatous disease (CGD) occurs most commonly due to an X-linked mutation affecting NADPH oxidase. Deficiency of this enzyme leads to an inability of neutrophils to form the oxidative burst necessary to kill organisms in their phagolysosomes. CGD can be diagnosed by absence of fluorescent green pigment on dihydrorhodamine flow cytometry testing or an abnormal nitroblue tetrazolium test.

- **Nitroblue tetrazolium (NBT)** testing involves adding NBT to a sample of the patient's neutrophils. Properly functioning neutrophils produce reactive oxygen species that reduce the yellow or colorless NBT to **dark blue** formazan that precipitates within the cells.
- **Dihydrorhodamine (DHR)** testing assesses the production of superoxide radicals by measuring the conversion of DHR to rhodamine, a **fluorescent green** compound that can be detected on flow cytometry.

Patients with deficient NADPH oxidase activity have abnormal NBT testing (ie, no change in color) and an absence of fluorescence on DHR flow cytometry.

(Choice A) Adenosine deaminase deficiency is an autosomal recessive disorder that is the second most common cause of severe combined immunodeficiency. This condition results in a profound decrease in B and T lymphocytes with variable immunoglobulin deficiencies.

(Choice B) Cytochrome c oxidase is a multi-subunit complex that acts as the terminal enzyme of the mitochondrial respiratory chain. Deficiency is most commonly due to autosomal recessive mutations and results in variable myopathic and encephalopathic findings.

(Choice C) Myeloperoxidase is an enzyme found in neutrophil azurophilic granules that aids in intracellular killing by catalyzing the production of hypochlorite (bleach) from hydrogen peroxide and chloride. Myeloperoxidase deficiency results in recurrent *Candida* infections. DHR fluorescence can be slightly reduced with impaired activity of this enzyme, but absence of fluorescence on DHR testing in a child with severe staphylococcal infections is more characteristic of CGD.

(Choice E) Pyruvate kinase deficiency is a common cause of chronic hemolytic anemia.

Educational objective:
Chronic granulomatous disease (CGD) occurs most commonly due to an X-linked mutation affecting NADPH oxidase. Deficiency of this enzyme leads to an inability of neutrophils to form the oxidative burst necessary to kill organisms in their phagolysosomes. CGD can be diagnosed by absence of fluorescent green pigment on dihydrorhodamine flow cytometry testing or an abnormal nitroblue tetrazolium test.

Pathophysiology	Allergy & Immunology	Primary immunodeficiency disorder
Subject	System	Topic

Copyright © UWorld. All rights reserved.

A 7-month-old boy is brought to the physician by his parents due to irritability and white patches in his mouth. His past medical history is significant for 3 episodes of otitis media and 2 episodes of bronchiolitis that have required hospitalization. He also has a history of chronic loose stools. The child is small for his age and ill-appearing. Head and neck examination shows white patches consistent with oral candidiasis but is otherwise normal. Auscultation of the lungs shows expiratory wheezing. Cardiac examination is within normal limits. Laboratory results are as follows:

Sodium	140 mEq/L
Potassium	3.8 mEq/L
Chloride	98 mEq/L
Bicarbonate	24 mEq/L
Calcium	9.6 mg/dL

Serum protein electrophoresis shows a very low gamma globulin level. Chest x-ray reveals an absent thymic shadow. Which of the following is the most likely diagnosis?

- A. Common variable immunodeficiency
- B. DiGeorge syndrome
- C. Severe combined immunodeficiency
- D. Wiskott-Aldrich syndrome
- E. X-linked agammaglobulinemia

Submit

A 7-month-old boy is brought to the physician by his parents due to irritability and white patches in his mouth. His past medical history is significant for 3 episodes of otitis media and 2 episodes of bronchiolitis that have required hospitalization. He also has a history of chronic loose stools. The child is small for his age and ill-appearing. Head and neck examination shows white patches consistent with oral candidiasis but is otherwise normal. Auscultation of the lungs shows expiratory wheezing. Cardiac examination is within normal limits. Laboratory results are as follows:

Sodium	140 mEq/L
Potassium	3.8 mEq/L
Chloride	98 mEq/L
Bicarbonate	24 mEq/L
Calcium	9.6 mg/dL

Serum protein electrophoresis shows a very low gamma globulin level. Chest x-ray reveals an absent thymic shadow. Which of the following is the most likely diagnosis?

A. Common variable immunodeficiency (2%)
B. DiGeorge syndrome (40%)
✓ C. Severe combined immunodeficiency (45%)
D. Wiskott-Aldrich syndrome (1%)
E. X-linked agammaglobulinemia (9%)

Omitted
45%
01 sec
06/27/2020

Explanation

Distinctive features of selected primary immunodeficiency disorders	
Condition	**Characteristic features**
Ataxia-telangiectasia	• Ataxia • Telangiectasias • Sinopulmonary infections
Chédiak-Higashi syndrome	• Oculocutaneous albinism • Pyogenic infections • Progressive neurologic dysfunction
Chronic granulomatous disease	• Severe bacterial & fungal infections • Granuloma formation
DiGeorge syndrome	• Congenital heart disease • Dysmorphic facies • Hypocalcemia
Severe combined immunodeficiency	• Severe bacterial & viral infections in infancy • Chronic diarrhea • Mucocutaneous candidiasis
Terminal complement	• Recurrent *Neisseria* infection

Distinctive features of selected primary immunodeficiency disorders

Condition	Characteristic features
Ataxia-telangiectasia	• Ataxia • Telangiectasias • Sinopulmonary infections
Chédiak-Higashi syndrome	• Oculocutaneous albinism • Pyogenic infections • Progressive neurologic dysfunction
Chronic granulomatous disease	• Severe bacterial & fungal infections • Granuloma formation
DiGeorge syndrome	• Congenital heart disease • Dysmorphic facies • Hypocalcemia
Severe combined immunodeficiency	• Severe bacterial & viral infections in infancy • Chronic diarrhea • Mucocutaneous candidiasis
Terminal complement deficiency	• Recurrent *Neisseria* infection

	• Cardiopulmonary infections
Chédiak-Higashi syndrome	• Oculocutaneous albinism • Pyogenic infections • Progressive neurologic dysfunction
Chronic granulomatous disease	• Severe bacterial & fungal infections • Granuloma formation
DiGeorge syndrome	• Congenital heart disease • Dysmorphic facies • Hypocalcemia
Severe combined immunodeficiency	• Severe bacterial & viral infections in infancy • Chronic diarrhea • Mucocutaneous candidiasis
Terminal complement deficiency	• Recurrent *Neisseria* infection
Wiskott-Aldrich syndrome	• Recurrent infections that worsen with age • Easy bleeding • Eczema

©UWorld

Severe combined immune deficiency (SCID) is a life-threatening immunodeficiency syndrome that presents in **infancy**. It is caused by a variety of mutations in different genes that result in impaired T and B cell development and function. This leads to compromised cell-mediated and humoral immunity with the eventual development of **severe viral and bacterial infections** as maternal immunity wanes. Other common features include mucocutaneous candidiasis, persistent diarrhea, and failure to thrive. Laboratory studies show very low or **absent CD3+ T cells** and

©UWorld

Severe combined immune deficiency (SCID) is a life-threatening immunodeficiency syndrome that presents in **infancy**. It is caused by a variety of mutations in different genes that result in impaired T and B cell development and function. This leads to compromised cell-mediated and humoral immunity with the eventual development of **severe viral and bacterial infections** as maternal immunity wanes. Other common features include mucocutaneous candidiasis, persistent diarrhea, and failure to thrive. Laboratory studies show very low or **absent CD3+ T cells** and **hypogammaglobulinemia**. Thymic hypoplasia or aplasia is another common finding in infants with SCID due to severe T cell deficiency.

(Choice A) Common variable immunodeficiency is a heterogenous condition caused by B and T cell dysfunction and characterized by hypogammaglobulinemia. It presents with recurrent infections in adults and children (after the neonatal period). While not entirely unaffected, cell-mediated immunity is not as impaired as in SCID and thymic aplasia is unlikely.

(Choice B) DiGeorge syndrome (DGS) classically presents with craniofacial abnormalities, conotruncal cardiac anomalies, hypoplastic thymus, and hypocalcemia resulting from parathyroid hypoplasia. Immunodeficiency can also occur and is related to the degree of thymic hypoplasia. Although complete DGS (<1% of cases) is a form of SCID, the absence of other characteristic findings makes DGS a less likely diagnosis.

(Choice D) In Wiskott-Aldrich syndrome, functioning of both T and B cells is impaired due to abnormal cytoskeletal functioning. Patients experience recurrent viral, bacterial, and fungal infections that generally worsen with age. However, Wiskott-Aldrich syndrome also typically causes bleeding due to thrombocytopenia and eczema.

(Choice E) X-linked (Bruton's) agammaglobulinemia is an immunodeficiency syndrome caused by insufficient production of mature B cells, which predisposes mainly to recurrent infections with encapsulated pyogenic bacteria (eg, *Streptococcus pneumoniae*, *Hemophilus influenzae* type B). The quantity and functioning of T cells is generally not affected, so an absent thymic shadow is unlikely.

Educational objective:
Severe combined immune deficiency is characterized by combined T and B cell dysfunction. It is a life-threatening condition that presents in infancy with severe bacterial and viral infections; mucocutaneous candidiasis; persistent diarrhea; and failure to thrive. Laboratory findings include absent T cells and hypogammaglobulinemia. The thymic shadow is not usually present due to severe T cell deficiency.

References

- Educational paper. The expanding clinical and immunological spectrum of severe combined immunodeficiency.
- Educational paper: Primary immunodeficiencies in children: a diagnostic challenge.

hypogammaglobulinemia. It presents with recurrent infections in adults and children (after the neonatal period). While not entirely unaffected, cell-mediated immunity is not as impaired as in SCID and thymic aplasia is unlikely.

(Choice B) DiGeorge syndrome (DGS) classically presents with craniofacial abnormalities, conotruncal cardiac anomalies, hypoplastic thymus, and hypocalcemia resulting from parathyroid hypoplasia. Immunodeficiency can also occur and is related to the degree of thymic hypoplasia. Although complete DGS (<1% of cases) is a form of SCID, the absence of other characteristic findings makes DGS a less likely diagnosis.

(Choice D) In Wiskott-Aldrich syndrome, functioning of both T and B cells is impaired due to abnormal cytoskeletal functioning. Patients experience recurrent viral, bacterial, and fungal infections that generally worsen with age. However, Wiskott-Aldrich syndrome also typically causes bleeding due to thrombocytopenia and eczema.

(Choice E) X-linked (Bruton's) agammaglobulinemia is an immunodeficiency syndrome caused by insufficient production of mature B cells, which predisposes mainly to recurrent infections with encapsulated pyogenic bacteria (eg, *Streptococcus pneumoniae*, *Hemophilus influenzae* type B). The quantity and functioning of T cells is generally not affected, so an absent thymic shadow is unlikely.

Educational objective:
Severe combined immune deficiency is characterized by combined T and B cell dysfunction. It is a life-threatening condition that presents in infancy with severe bacterial and viral infections; mucocutaneous candidiasis; persistent diarrhea; and failure to thrive. Laboratory findings include absent T cells and hypogammaglobulinemia. The thymic shadow is not usually present due to severe T cell deficiency.

References

- Educational paper. The expanding clinical and immunological spectrum of severe combined immunodeficiency.
- Educational paper: Primary immunodeficiencies in children: a diagnostic challenge.
- Clinical immunology review series: an approach to the patient with recurrent infections in childhood.

Pathophysiology	Allergy & Immunology	Severe combined immunodeficiency disease
Subject	System	Topic

Copyright © UWorld. All rights reserved.

An infant is born with facial dysmorphia and a cleft palate. Further evaluation reveals a heart condition with a right-to-left shunt and the absence of a thymic shadow on x-ray. The infant experiences frequent and recurrent sinopulmonary infections. Examination of this patient's lymph nodes will most likely show poor development of which of the following structures?

A. Cortical follicles

B. Medullary sinuses

C. Medullary cords

D. Paracortex region

E. Subcapsular sinuses

Submit

An infant is born with facial dysmorphia and a cleft palate. Further evaluation reveals a heart condition with a right-to-left shunt and the absence of a thymic shadow on x-ray. The infant experiences frequent and recurrent sinopulmonary infections. Examination of this patient's lymph nodes will most likely show poor development of which of the following structures?

A. Cortical follicles (10%)
B. Medullary sinuses (4%)
C. Medullary cords (3%)
✓ D. Paracortex region (79%)
E. Subcapsular sinuses (0%)

Omitted
Correct answer
D

79%
Answered correctly

02 secs
Time Spent

04/22/2020
Last Updated

Explanation

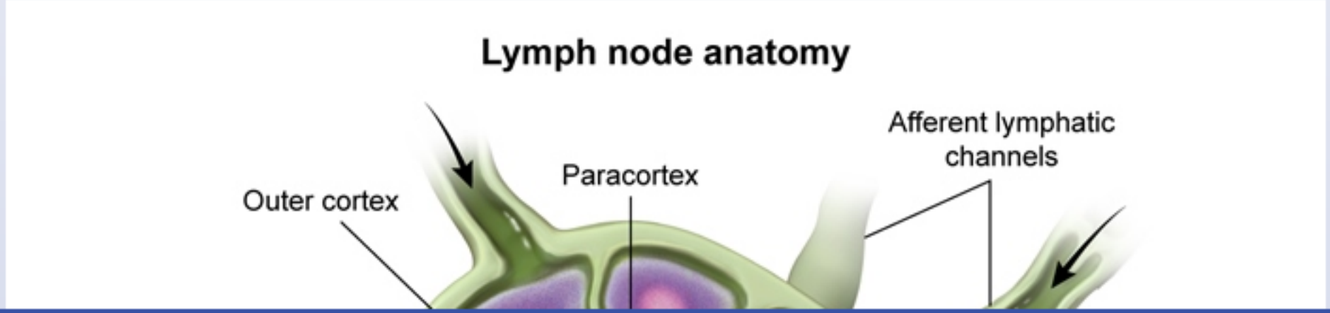

Lymph node anatomy

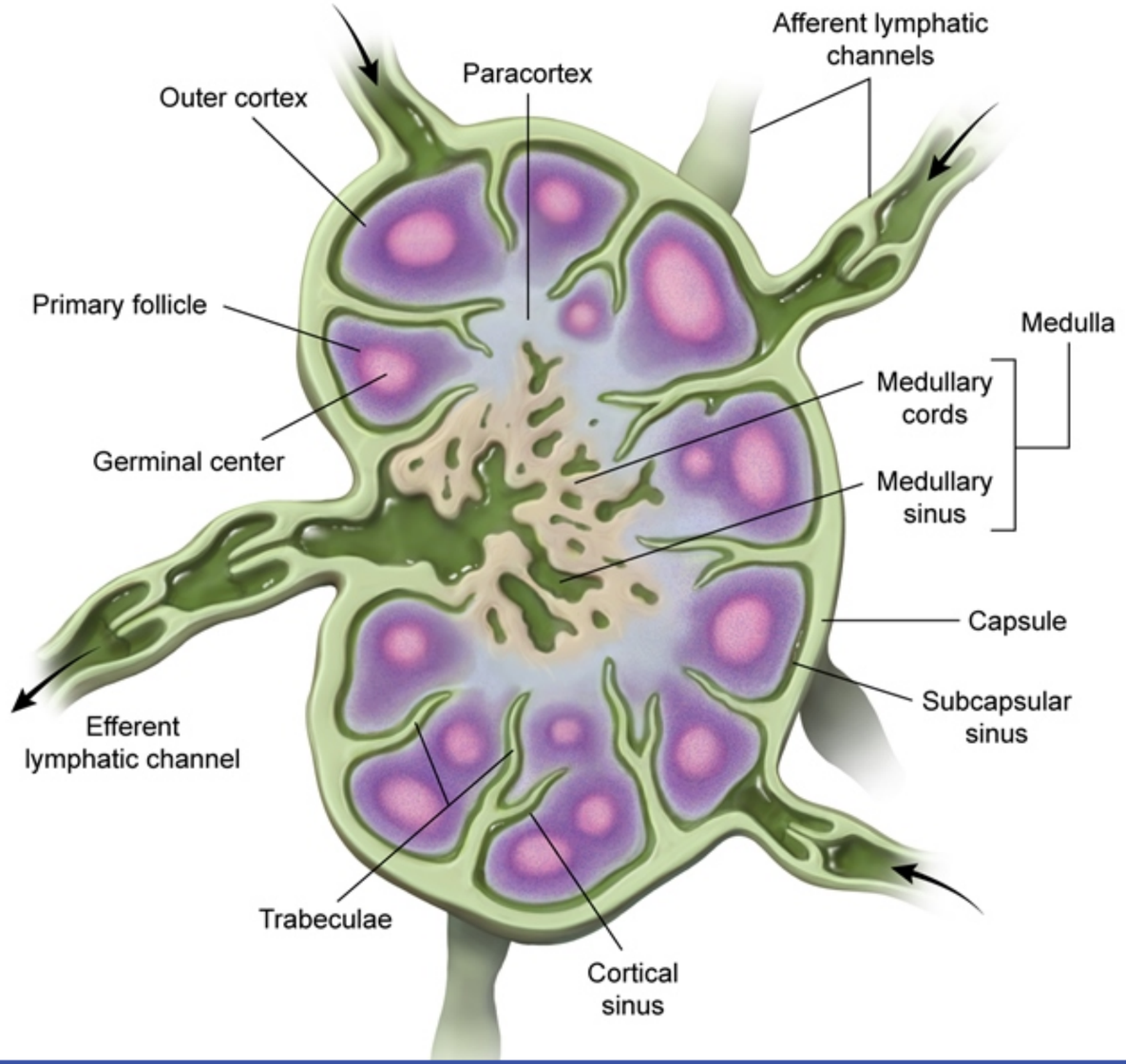

DiGeorge syndrome is caused by maldevelopment of the third and fourth pharyngeal pouch derivatives. Immunodeficiency can result from thymic aplasia, which leads to an extreme deficiency in the number of mature T lymphocytes. Although T cells are synthesized in the bone marrow, they require processing in the thymus in order to mature and mount effective immune responses. Patients are thus predisposed to recurrent infections by viral, fungal, protozoan, and intracellular bacterial pathogens.

The paracortex is the region of the lymph node populated primarily by T lymphocytes and dendritic cells. It lies internal to the cortex, between the follicles and medulla. Dendritic cells present antigens that they collect from the blood and lymph to the aggregated T lymphocytes in this region. The paracortex becomes enlarged by the proliferation of T lymphocytes during adaptive cellular immune responses (eg, viral infections). In DiGeorge syndrome, this region is poorly developed due to a deficiency of mature T lymphocytes.

(Choice A) Located in the outer cortex, the follicles are sites of B lymphocyte localization and proliferation. Primary follicles are dense and dormant; secondary follicles have a pale germinal center containing proliferating B cells and follicular dendritic cells. In agammaglobulinemia, germinal centers and primary lymphoid follicles do not form due to an absence of B cells.

(Choices B and C) The medulla of the lymph node consists of medullary cords and sinuses. The medullary cords contain B cells, plasma cells, and macrophages, and the medullary sinuses contain reticular cells and macrophages.

(Choice E) The subcapsular sinuses are the regions lying between the capsule and cortex of the lymph node. They are in direct communication with afferent lymphatic vessels and the cortical sinuses that line the trabecula. The cortical sinuses are continuous with the medullary sinuses and the single efferent lymphatic channel exiting the hilum.

Educational objective:
DiGeorge syndrome causes an extreme deficiency in the number of mature T lymphocytes, leading to poor development of the lymph node paracortex. In contrast, agammaglobulinemia causes an absence of B cells, preventing primary lymphoid follicles and germinal centers from forming in the lymph node cortex.

Pathophysiology	Allergy & Immunology	Primary immunodeficiency disorder
Subject	System	Topic

Copyright © UWorld. All rights reserved.

A 23-year-old woman comes to the office due to sharp, right-sided chest pain, fatigue, and fever for the past week. The chest pain is worsened with deep breathing. She has had no associated expectoration or shortness of breath. For the past 6 months, the patient also has had intermittent joint pains, predominantly in the knees and hands. She is sexually active with one male partner and uses an intrauterine device for contraception. Temperature is 38.3 C (100.9 F), blood pressure is 120/70 mm Hg, pulse is 89/min, and respirations are 18/min. BMI is 24 kg/m^2. Examination shows mild erythema over the cheeks and a scratching sound over the right lower lung with breathing. Heart sounds are normal. There is no joint swelling. Which of the following tests is most useful in confirming the diagnosis?

A. Anti–double-stranded DNA antibodies

B. Antistreptolysin O titers

C. Nucleic acid amplification test of cervical swab

D. Rheumatoid factor assay

E. Serologic test for syphilis

Submit

A 23-year-old woman comes to the office due to sharp, right-sided chest pain, fatigue, and fever for the past week. The chest pain is worsened with deep breathing. She has had no associated expectoration or shortness of breath. For the past 6 months, the patient also has had intermittent joint pains, predominantly in the knees and hands. She is sexually active with one male partner and uses an intrauterine device for contraception. Temperature is 38.3 C (100.9 F), blood pressure is 120/70 mm Hg, pulse is 89/min, and respirations are 18/min. BMI is 24 kg/m^2. Examination shows mild erythema over the cheeks and a scratching sound over the right lower lung with breathing. Heart sounds are normal. There is no joint swelling. Which of the following tests is most useful in confirming the diagnosis?

- ✓ A. Anti–double-stranded DNA antibodies (76%)
- B. Antistreptolysin O titers (7%)
- C. Nucleic acid amplification test of cervical swab (8%)
- D. Rheumatoid factor assay (4%)
- E. Serologic test for syphilis (3%)

Omitted
Correct answer
A

76%
Answered correctly

01 sec
Time Spent

03/03/2020
Last Updated

Explanation

Systemic lupus erythematosus	
Clinical presentation	• Gradual symptom onset • Malar or discoid rash

Systemic lupus erythematosus	
Clinical presentation	• Gradual symptom onset • Malar or discoid rash • Joint, renal, serosal &/or neurologic involvement
Laboratory abnormalities	• Anemia, leukopenia, thrombocytopenia • Positive **ANA**, **anti–double-stranded DNA**, anti-Smith • Low complement levels, increased immune complexes

ANA = antinuclear antibodies.

This young patient has pleuritis (chest pain worse with breathing, pleural rub), arthralgias, fever, and an erythematous rash on the cheeks. This presentation is concerning for **systemic lupus erythematosus** (SLE), a chronic inflammatory disease characterized by autoantibodies that bind self-antigens. Particular autoantibodies that are useful in the diagnosis of SLE include:

1. **Antinuclear antibodies** are found in virtually all patients with SLE but also in many other autoimmune disorders (ie, high sensitivity, low specificity).
2. **Anti–double-stranded DNA antibodies** are **highly specific** for SLE, but only approximately 60% of patients have high titers (ie, low sensitivity, high specificity).
3. **Anti-Smith antibodies** (ie, antibodies against small nuclear ribonucleoproteins) are present in 20%-30% of patients but are also highly specific.

Common laboratory abnormalities include **low C3 and C4** levels (due to activation of complement) and **elevated inflammatory markers** (eg, C-reactive protein, erythrocyte sedimentation rate). Hematologic abnormalities can include anemia, leukopenia, and thrombocytopenia, which occur due to chronic inflammatory effects on bone marrow and autoimmune hemolysis. Renal involvement can result in elevated serum creatinine, proteinuria, hematuria, or red cell casts visible on urinalysis.

(Choice B) Antibodies to streptolysin O indicate recent streptococcal infection and are useful in the diagnosis of certain immune sequelae (eg, glomerulonephritis, rheumatic fever). This patient has arthralgias, but no other major features of rheumatic fever (ie, carditis, subcutaneous nodules, erythema marginatum, Sydenham chorea).

ANA = antinuclear antibodies.

This young patient has pleuritis (chest pain worse with breathing, pleural rub), arthralgias, fever, and an erythematous rash on the cheeks. This presentation is concerning for **systemic lupus erythematosus** (SLE), a chronic inflammatory disease characterized by autoantibodies that bind self-antigens. Particular autoantibodies that are useful in the diagnosis of SLE include:

1. **Antinuclear antibodies** are found in virtually all patients with SLE but also in many other autoimmune disorders (ie, high sensitivity, low specificity).
2. **Anti–double-stranded DNA antibodies** are **highly specific** for SLE, but only approximately 60% of patients have high titers (ie, low sensitivity, high specificity).
3. **Anti-Smith antibodies** (ie, antibodies against small nuclear ribonucleoproteins) are present in 20%-30% of patients but are also highly specific.

Common laboratory abnormalities include **low C3 and C4** levels (due to activation of complement) and **elevated inflammatory markers** (eg, C-reactive protein, erythrocyte sedimentation rate). Hematologic abnormalities can include anemia, leukopenia, and thrombocytopenia, which occur due to chronic inflammatory effects on bone marrow and autoimmune hemolysis. Renal involvement can result in elevated serum creatinine, proteinuria, hematuria, or red cell casts visible on urinalysis.

(Choice B) Antibodies to streptolysin O indicate recent streptococcal infection and are useful in the diagnosis of certain immune sequelae (eg, glomerulonephritis, rheumatic fever). This patient has arthralgias, but no other major features of rheumatic fever (ie, carditis, subcutaneous nodules, erythema marginatum, Sydenham chorea).

(Choice C) Acute cervicitis is a common cause of fever in young, sexually active women. Evaluation commonly includes nucleic acid amplification testing (NAAT) for organisms such as gonorrhea, chlamydia, and trichomoniasis. Although disseminated gonorrhea can cause arthralgias and rash, pleuritis is not typical.

(Choice D) Rheumatoid factor is an IgM antibody directed against the Fc portion of human IgG. It is classically associated with rheumatoid arthritis, although it may also be seen in other autoimmune diseases (including SLE) and is nonspecific. Rheumatoid arthritis can cause arthralgias and lung involvement, but rash is unexpected and joint swelling is usually prominent.

(Choice E) Nontreponemal serologic tests (eg, RPR, VDRL) are frequently used to screen for syphilis. Although secondary syphilis can manifest with synovitis and rash, it typically involves the palms and soles and pleural involvement is rare.

3. **Anti-Smith antibodies** (ie, antibodies against small nuclear ribonucleoproteins) are present in 20%-30% of patients but are also highly specific.

Common laboratory abnormalities include **low C3 and C4** levels (due to activation of complement) and **elevated inflammatory markers** (eg, C-reactive protein, erythrocyte sedimentation rate). Hematologic abnormalities can include anemia, leukopenia, and thrombocytopenia, which occur due to chronic inflammatory effects on bone marrow and autoimmune hemolysis. Renal involvement can result in elevated serum creatinine, proteinuria, hematuria, or red cell casts visible on urinalysis.

(Choice B) Antibodies to streptolysin O indicate recent streptococcal infection and are useful in the diagnosis of certain immune sequelae (eg, glomerulonephritis, rheumatic fever). This patient has arthralgias, but no other major features of rheumatic fever (ie, carditis, subcutaneous nodules, erythema marginatum, Sydenham chorea).

(Choice C) Acute cervicitis is a common cause of fever in young, sexually active women. Evaluation commonly includes nucleic acid amplification testing (NAAT) for organisms such as gonorrhea, chlamydia, and trichomoniasis. Although disseminated gonorrhea can cause arthralgias and rash, pleuritis is not typical.

(Choice D) Rheumatoid factor is an IgM antibody directed against the Fc portion of human IgG. It is classically associated with rheumatoid arthritis, although it may also be seen in other autoimmune diseases (including SLE) and is nonspecific. Rheumatoid arthritis can cause arthralgias and lung involvement, but rash is unexpected and joint swelling is usually prominent.

(Choice E) Nontreponemal serologic tests (eg, RPR, VDRL) are frequently used to screen for syphilis. Although secondary syphilis can manifest with synovitis and rash, it typically involves the palms and soles and pleural involvement is rare.

Educational objective:
Antinuclear antibodies are found in almost all patients with systemic lupus erythematosus but are also found in many other autoimmune disorders and have low specificity. Anti–double-stranded DNA antibodies and anti-Smith antibodies have lower sensitivity but higher specificity.

Pathophysiology	Allergy & Immunology	SLE
Subject	System	Topic

Copyright © UWorld. All rights reserved.

A 32-year-old man is started on infliximab for treatment of refractory Crohn disease. Ten days later, he develops joint pain and a pruritic skin rash. Skin biopsy shows scattered areas of fibrinoid necrosis and neutrophil infiltration involving his small blood vessels. Which of the following findings is most likely to accompany this patient's condition?

A. *Candida* antigen anergy

B. Decreased serum C3 level

C. Increased serum IgE level

D. Low serum IgA level

E. Neutrophilia

F. Severe thrombocytopenia

Submit

A 32-year-old man is started on infliximab for treatment of refractory Crohn disease. Ten days later, he develops joint pain and a pruritic skin rash. Skin biopsy shows scattered areas of fibrinoid necrosis and neutrophil infiltration involving his small blood vessels. Which of the following findings is most likely to accompany this patient's condition?

- A. *Candida* antigen anergy (7%)
- ✓ B. Decreased serum C3 level (40%)
- C. Increased serum IgE level (13%)
- D. Low serum IgA level (8%)
- E. Neutrophilia (14%)
- F. Severe thrombocytopenia (14%)

Omitted
Correct answer
B

40%
Answered correctly

01 sec
Time Spent

06/21/2020
Last Updated

Explanation

Hypersensitivity reactions			
	Humoral components	Cellular components	Examples
Type I	• IgE	• Basophils	• Anaphylaxis

Hypersensitivity reactions			
	Humoral components	**Cellular components**	**Examples**
Type I (immediate)	• **IgE**	• Basophils • Mast cells	• Anaphylaxis • Allergies
Type II (cytotoxic)	• **IgG & IgM** autoantibodies • Complement activation	• NK cells • Eosinophils • Neutrophils • Macrophages	• Autoimmune hemolytic anemia • Goodpasture syndrome
Type III (immune complex)	• Deposition of **antibody-antigen complexes** • Complement activation	• Neutrophils	• Serum sickness • PSGN • Lupus nephritis
Type IV (delayed type)	• None	• **T cells** • **Macrophages**	• Contact dermatitis • Tuberculin skin test

NK = natural killer; **PSGN** = poststreptococcal glomerulonephritis.

This patient's symptoms and biopsy findings are suggestive of **acute serum sickness**, a condition caused by tissue deposition of circulating immune complexes (**type III hypersensitivity**). The most common manifestations include fever, pruritic skin rash, and arthralgias that begin 7-14 days after exposure to an antigen. Lymphadenopathy and proteinuria may also occur in some patients. Histologic examination of affected tissues typically shows small vessel vasculitis with **fibrinoid necrosis** and intense **neutrophil infiltration**. Deposition of IgG and/or IgM complement-fixing antibodies results in localized complement consumption and **hypocomplementemia** (decreased serum C3 levels).

Serum sickness can occur following administration of antigenic heterologous proteins such as **chimeric monoclonal antibodies** (eg, rituximab

This patient's symptoms and biopsy findings are suggestive of **acute serum sickness**, a condition caused by tissue deposition of circulating immune complexes (**type III hypersensitivity**). The most common manifestations include fever, pruritic skin rash, and arthralgias that begin 7-14 days after exposure to an antigen. Lymphadenopathy and proteinuria may also occur in some patients. Histologic examination of affected tissues typically shows small vessel vasculitis with **fibrinoid necrosis** and intense **neutrophil infiltration**. Deposition of IgG and/or IgM complement-fixing antibodies results in localized complement consumption and **hypocomplementemia** (decreased serum C3 levels).

Serum sickness can occur following administration of antigenic heterologous proteins such as **chimeric monoclonal antibodies** (eg, rituximab and infliximab) or **nonhuman immunoglobulins** (eg, venom antitoxins). A serum sickness–like reaction is also associated with the use of certain nonprotein drugs (eg, penicillin, cefaclor, and trimethoprim-sulfamethoxazole).

(Choice A) Anergy to cutaneously applied *Candida* antigens would be indicative of depressed cell-mediated immunity. Cell-mediated immunity is involved in the pathogenesis of type IV (delayed) hypersensitivity.

(Choice C) Increased serum IgE levels are typically found in atopic individuals prone to IgE-mediated (type I) hypersensitivity reactions. Type I reactions cause vasodilation and tissue edema and inflammatory infiltration; they do not cause vasculitis with fibrinoid necrosis.

(Choice D) Deposition of IgA-containing immune complexes is involved in the pathogenesis of Henoch-Schönlein purpura in pediatric patients. IgA does not play an important role in type III hypersensitivity.

(Choice E) Serum sickness causes release of the C5a complement fragment (a neutrophil chemoattractant) at sites of immune complex deposition. This leads to neutropenia (not neutrophilia) due to extensive neutrophilic marginalization and tissue infiltration. In addition, infliximab and other TNF-alpha inhibitors can also cause neutropenia.

(Choice F) Mild thrombocytopenia has been associated with serum sickness due to platelet consumption at the site of active vascular inflammation. However, severe thrombocytopenia is unlikely to occur.

Educational objective:
Serum sickness is a type III hypersensitivity reaction to nonhuman proteins characterized by vasculitis resulting from tissue deposition of circulating immune complexes. Clinical findings include fever, pruritic skin rash, arthralgias, and low serum C3 and C4 complement levels.

Pathophysiology Allergy & Immunology Serum sickness

typically shows small vessel vasculitis with **fibrinoid necrosis** and intense **neutrophil infiltration**. Deposition of IgG and/or IgM complement-fixing antibodies results in localized complement consumption and **hypocomplementemia** (decreased serum C3 levels).

Serum sickness can occur following administration of antigenic heterologous proteins such as **chimeric monoclonal antibodies** (eg, rituximab and infliximab) or **nonhuman immunoglobulins** (eg, venom antitoxins). A serum sickness–like reaction is also associated with the use of certain nonprotein drugs (eg, penicillin, cefaclor, and trimethoprim-sulfamethoxazole).

(Choice A) Anergy to cutaneously applied *Candida* antigens would be indicative of depressed cell-mediated immunity. Cell-mediated immunity is involved in the pathogenesis of type IV (delayed) hypersensitivity.

(Choice C) Increased serum IgE levels are typically found in atopic individuals prone to IgE-mediated (type I) hypersensitivity reactions. Type I reactions cause vasodilation and tissue edema and inflammatory infiltration; they do not cause vasculitis with fibrinoid necrosis.

(Choice D) Deposition of IgA-containing immune complexes is involved in the pathogenesis of Henoch-Schönlein purpura in pediatric patients. IgA does not play an important role in type III hypersensitivity.

(Choice E) Serum sickness causes release of the C5a complement fragment (a neutrophil chemoattractant) at sites of immune complex deposition. This leads to neutropenia (not neutrophilia) due to extensive neutrophilic marginalization and tissue infiltration. In addition, infliximab and other TNF-alpha inhibitors can also cause neutropenia.

(Choice F) Mild thrombocytopenia has been associated with serum sickness due to platelet consumption at the site of active vascular inflammation. However, severe thrombocytopenia is unlikely to occur.

Educational objective:
Serum sickness is a type III hypersensitivity reaction to nonhuman proteins characterized by vasculitis resulting from tissue deposition of circulating immune complexes. Clinical findings include fever, pruritic skin rash, arthralgias, and low serum C3 and C4 complement levels.

Pathophysiology	Allergy & Immunology	Serum sickness
Subject	System	Topic

Copyright © UWorld. All rights reserved.

A 7-year-old boy with a history of recurrent granulomatous skin infections and a prior episode of *Aspergillus* pneumonia undergoes a partial hepatectomy to treat a poorly draining liver abscess. Genetic analysis reveals an inactivating mutation affecting a structural component of a neutrophil oxidase enzyme. This patient most likely has increased vulnerability to infections caused by which of the following pathogens?

- A. *Burkholderia cepacia*
- B. *Enterococcus faecalis*
- C. *Giardia lamblia*
- D. Herpes simplex virus type 1
- E. *Streptococcus pneumoniae*
- F. *Streptococcus pyogenes*

Submit

A 7-year-old boy with a history of recurrent granulomatous skin infections and a prior episode of *Aspergillus* pneumonia undergoes a partial hepatectomy to treat a poorly draining liver abscess. Genetic analysis reveals an inactivating mutation affecting a structural component of a neutrophil oxidase enzyme. This patient most likely has increased vulnerability to infections caused by which of the following pathogens?

- ✓ A. *Burkholderia cepacia* (33%)
- B. *Enterococcus faecalis* (11%)
- C. *Giardia lamblia* (9%)
- D. Herpes simplex virus type 1 (1%)
- E. *Streptococcus pneumoniae* (29%)
- F. *Streptococcus pyogenes* (13%)

Omitted
Correct answer
A

33%
Answered correctly

01 sec
Time Spent

05/04/2020
Last Updated

Explanation

Features of chronic granulomatous disease	
Pathogenesis	• Inactivating mutation affecting **NADPH oxidase** • Impaired respiratory burst inhibits phagocytic **intracellular killing**
	• Recurrent infections with **catalase-positive** bacteria & fungi

Features of chronic granulomatous disease	
Pathogenesis	• Inactivating mutation affecting **NADPH oxidase** • Impaired respiratory burst inhibits phagocytic **intracellular killing**
Clinical manifestations	• Recurrent infections with **catalase-positive** bacteria & fungi • Lungs, skin, lymph nodes & liver most commonly involved • Diffuse **granuloma formation**
Diagnosis	Measurement of **neutrophil superoxide production**: • DHR flow cytometry (preferred) • NBT testing

DHR = dihydrorhodamine; NBT = nitroblue tetrazolium.

This patient has **chronic granulomatous disease (CGD)**, a condition that results in **recurrent bacterial and fungal infections** due to **impaired intracellular killing** by phagocytes. It is caused by a genetic defect in the **NADPH oxidase** complex. NADPH oxidase normally functions to transfer an electron from NADPH to oxygen, resulting in the production of superoxide ($O_2^{\cdot-}$) and subsequent formation of other **reactive oxygen species** such as hydroxyl radicals ($HO^{\cdot}$) and hydrogen peroxide (H_2O_2). These oxidants have direct microbicidal activity and also function to activate **granule proteases** (eg, elastase, cathepsin G) that destroy engulfed pathogens.

Most microorganisms produce hydrogen peroxide as a waste product of metabolism. Catalase-negative organisms are unable to prevent the accumulation of hydrogen peroxide within phagosomes, which allows the phagocytes to generate potent microbicidal agents (eg, hypochlorite) even when host superoxide production is impaired. As a result, the bacteria and fungi responsible for infections in CGD are **catalase-positive** organisms that can destroy their own hydrogen peroxide. The most common organisms are ***Staphylococcus aureus, Burkholderia cepacia, Serratia marcescens, Nocardia***, and ***Aspergillus***.

(Choices B, E, and F) *Enterococcus faecalis, Streptococcus pneumoniae*, and *Streptococcus pyogenes* are catalase-negative bacteria and are not common pathogens in CGD.

This patient has **chronic granulomatous disease (CGD)**, a condition that results in **recurrent bacterial and fungal infections** due to **impaired intracellular killing** by phagocytes. It is caused by a genetic defect in the **NADPH oxidase** complex. NADPH oxidase normally functions to transfer an electron from NADPH to oxygen, resulting in the production of superoxide ($O_2^{\cdot-}$) and subsequent formation of other **reactive oxygen species** such as hydroxyl radicals ($HO^{\cdot}$) and hydrogen peroxide (H_2O_2). These oxidants have direct microbicidal activity and also function to activate **granule proteases** (eg, elastase, cathepsin G) that destroy engulfed pathogens.

Most microorganisms produce hydrogen peroxide as a waste product of metabolism. Catalase-negative organisms are unable to prevent the accumulation of hydrogen peroxide within phagosomes, which allows the phagocytes to generate potent microbicidal agents (eg, hypochlorite) even when host superoxide production is impaired. As a result, the bacteria and fungi responsible for infections in CGD are **catalase-positive** organisms that can destroy their own hydrogen peroxide. The most common organisms are ***Staphylococcus aureus, Burkholderia cepacia, Serratia marcescens, Nocardia***, and ***Aspergillus***.

(Choices B, E, and F) *Enterococcus faecalis, Streptococcus pneumoniae*, and *Streptococcus pyogenes* are catalase-negative bacteria and are not common pathogens in CGD.

(Choices C and D) Patients with CGD are not at increased risk of parasitic or viral infections.

Educational objective:
Chronic granulomatous disease (CGD) results from a genetic defect in NADPH oxidase. Normally, NADPH oxidase participates in the killing of microbes within neutrophil and macrophage phagolysosomes. Patients with CGD develop recurrent bacterial and fungal infections that are predominantly caused by 5 catalase-positive organisms: *Staphylococcus aureus, Burkholderia cepacia, Serratia marcescens, Nocardia*, and *Aspergillus*.

References

- Steven M. Holland. Chronic Granulomatous Disease. Clinic Rev Allerg Immunol (2010) 38:3-10.

Pathophysiology	Allergy & Immunology	Primary immunodeficiency disorder
Subject	System	Topic

Copyright © UWorld. All rights reserved.

A 4-year-old boy is evaluated for recurrent skin and respiratory infections. He has light skin and silvery hair. Horizontal nystagmus is present on eye examination. Peripheral blood smear demonstrates giant cytoplasmic granules in neutrophils and monocytes. The patient most likely has which of the following disorders?

A. Chédiak-Higashi syndrome
B. Chronic granulomatous disease
C. Complete albinism
D. DiGeorge syndrome
E. Phenylketonuria
F. Wiskott-Aldrich syndrome

Submit

A 4-year-old boy is evaluated for recurrent skin and respiratory infections. He has light skin and silvery hair. Horizontal nystagmus is present on eye examination. Peripheral blood smear demonstrates giant cytoplasmic granules in neutrophils and monocytes. The patient most likely has which of the following disorders?

- ✓ A. Chédiak-Higashi syndrome (80%)
- B. Chronic granulomatous disease (5%)
- C. Complete albinism (5%)
- D. DiGeorge syndrome (0%)
- E. Phenylketonuria (2%)
- F. Wiskott-Aldrich syndrome (6%)

Omitted
Correct answer
A

80%
Answered correctly

01 sec
Time Spent

07/01/2020
Last Updated

Explanation

Chédiak-Higashi syndrome

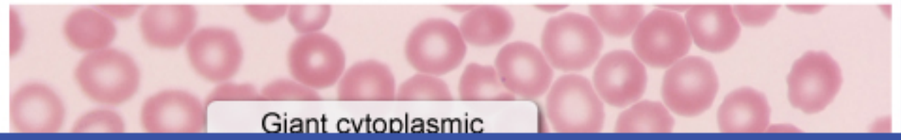

Chédiak-Higashi syndrome

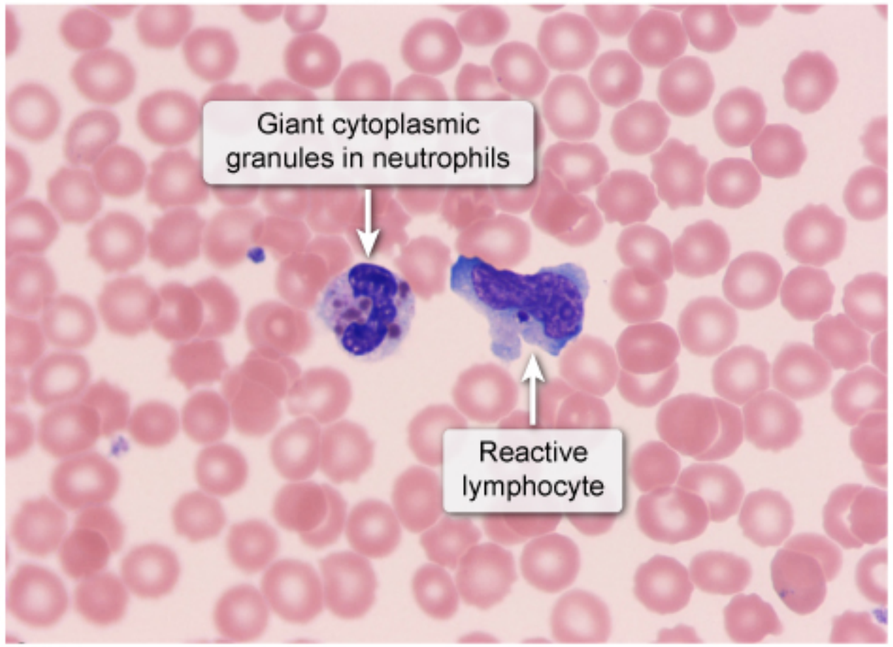

©UWorld

This patient has **Chédiak-Higashi syndrome** (CHS), an autosomal recessive disorder characterized by immunodeficiency, albinism, and neurologic defects that is usually diagnosed in childhood. In CHS, fusion of vesicles and transport of lysosomes are impaired, leading to defects in many cell types (eg, melanocytes, neutrophils) throughout the body. Neurologic defects associated with this condition include **nystagmus**, as well as progressive central and peripheral neurologic deterioration (eg, neuropathies, seizures). Abnormal melanin storage in melanocytes causes **partial oculocutaneous albinism** (eg, fair skin, silvery hair, light blue eyes).

The **immunodeficiency** in CHS results from a defect in natural killer cell function and **neutrophil** phagosome-lysosome fusion. This causes abnormal **giant lysosomal inclusions** that are visible on light microscopy of a peripheral blood smear. Loss of functional neutrophils leads to

©UWorld

This patient has **Chédiak-Higashi syndrome** (CHS), an autosomal recessive disorder characterized by immunodeficiency, albinism, and neurologic defects that is usually diagnosed in childhood. In CHS, fusion of vesicles and transport of lysosomes are impaired, leading to defects in many cell types (eg, melanocytes, neutrophils) throughout the body. Neurologic defects associated with this condition include **nystagmus**, as well as progressive central and peripheral neurologic deterioration (eg, neuropathies, seizures). Abnormal melanin storage in melanocytes causes **partial oculocutaneous albinism** (eg, fair skin, silvery hair, light blue eyes).

The **immunodeficiency** in CHS results from a defect in natural killer cell function and **neutrophil** phagosome-lysosome fusion. This causes abnormal **giant lysosomal inclusions** that are visible on light microscopy of a peripheral blood smear. Loss of functional neutrophils leads to **recurrent infections with pyogenic bacteria** (eg, *Staphylococcus*, *Streptococcus*, *Pneumococcus*).

(Choice B) In patients with chronic granulomatous disease (CGD), neutrophils are unable to kill catalase-producing organisms (eg, *Staphylococcus aureus*) due to a deficiency of NADPH oxidase. CGD is not associated with partial oculocutaneous albinism or giant cytoplasmic granules.

(Choice C) Albinism is a genodermatosis that results from defects in the production of melanin by melanocytes despite normal melanocyte number and location. Complete albinism is characterized by white hair, lightly pigmented irises (eg, blue to pink/red), and pink or white skin and due to a complete absence of tyrosinase. However, partial oculocutaneous albinism, recurrent infections, and intracytoplasmic granules are more characteristic of CHS.

(Choice D) DiGeorge syndrome is an immunodeficiency resulting from a deletion on chromosome 22 leading to maldevelopment of the third and fourth pharyngeal pouches. It is characterized by thymic and parathyroid hypoplasia, abnormal facies, and cardiac defects. Thymic hypoplasia causes deficient T cell maturation, which manifests with recurrent viral, fungal, and protozoal infections.

(Choice E) Phenylketonuria is caused by a deficiency of phenylalanine hydroxylase or tetrahydrobiopterin (an essential cofactor). Impaired conversion of phenylalanine to tyrosine leads to CNS abnormalities (eg, developmental delay, intellectual disability) along with a musty body odor.

(Choice F) Wiskott-Aldrich syndrome is an X-linked disorder characterized by immunodeficiency (combined B and T lymphocyte deficiency), eczema, and thrombocytopenia. Patients with this condition usually have prolonged bleeding and petechiae along with recurrent infections.

Educational objective:
Chédiak-Higashi syndrome is an autosomal recessive disorder affecting vesicle fusion and lysosome transport that results in neurologic

The **immunodeficiency** in CHS results from a defect in natural killer cell function and **neutrophil** phagosome-lysosome fusion. This causes abnormal **giant lysosomal inclusions** that are visible on light microscopy of a peripheral blood smear. Loss of functional neutrophils leads to **recurrent infections with pyogenic bacteria** (eg, *Staphylococcus*, *Streptococcus*, *Pneumococcus*).

(Choice B) In patients with chronic granulomatous disease (CGD), neutrophils are unable to kill catalase-producing organisms (eg, *Staphylococcus aureus*) due to a deficiency of NADPH oxidase. CGD is not associated with partial oculocutaneous albinism or giant cytoplasmic granules.

(Choice C) Albinism is a genodermatosis that results from defects in the production of melanin by melanocytes despite normal melanocyte number and location. Complete albinism is characterized by white hair, lightly pigmented irises (eg, blue to pink/red), and pink or white skin and due to a complete absence of tyrosinase. However, partial oculocutaneous albinism, recurrent infections, and intracytoplasmic granules are more characteristic of CHS.

(Choice D) DiGeorge syndrome is an immunodeficiency resulting from a deletion on chromosome 22 leading to maldevelopment of the third and fourth pharyngeal pouches. It is characterized by thymic and parathyroid hypoplasia, abnormal facies, and cardiac defects. Thymic hypoplasia causes deficient T cell maturation, which manifests with recurrent viral, fungal, and protozoal infections.

(Choice E) Phenylketonuria is caused by a deficiency of phenylalanine hydroxylase or tetrahydrobiopterin (an essential cofactor). Impaired conversion of phenylalanine to tyrosine leads to CNS abnormalities (eg, developmental delay, intellectual disability) along with a musty body odor.

(Choice F) Wiskott-Aldrich syndrome is an X-linked disorder characterized by immunodeficiency (combined B and T lymphocyte deficiency), eczema, and thrombocytopenia. Patients with this condition usually have prolonged bleeding and petechiae along with recurrent infections.

Educational objective:
Chédiak-Higashi syndrome is an autosomal recessive disorder affecting vesicle fusion and lysosome transport that results in neurologic abnormalities, partial albinism, and immunodeficiency caused by defective neutrophil and natural killer cell function.

Pathophysiology	Allergy & Immunology	Chediak higashi syndrome
Subject	System	Topic

Copyright © UWorld. All rights reserved.